

[OP069] SENSITIVITY OF OXYGEN CHALLENGE TEST IN PATIENTS WITH DIABETIC FOOT ULCER

Johana Venerová¹, Prague, Czech Republic , Jarmila Jirkovská¹, Prague, Czech Republic , Zdeněk Roth², Prague, Czech Republic , Lenka Vedralová¹, Prague, Czech Republic , Svatopluk Solarš¹, Prague, Czech Republic , Miroslav Zavoral¹, Prague, Czech Republic

¹Charles University, First Faculty of Medicine; Medical Department of the First Faculty of Medicine and Military University Hospital

²National Institute of Public Health; Centre of Toxicology and Health Safety

Thursday, May 14, 2015

Free Paper Session: Diabetic Foot 1

Aim: Oxygen challenge test with inhalation of 100% oxygen (stimulation test - ST) can increase sensitivity of transcutaneous oxymetry (TcPO₂) in detection of peripheral arterial disease (PAD) in patients with diabetic foot ulcer (DFU). The aim was to compare concordance of 5 different evaluations of ST (1-5) in PAD detection and to check sensitivity of each ST to angiographically verified stenosis.

Method: 28 consecutive patients (31 limbs) with inclusion criteria (DM, DFU Wagner ≥ 2 , clinical signs of ischaemia) treated in the period 02/2010 - 01/2014. Baseline TcPO₂ and ST with inhalation of 100% oxygen were measured. All patients were indicated for angiography and revascularisation. Stimulated TcPO₂-values were evaluated in 5 different manners: 1. TcPO₂ absolute value at the hindicate ischaemia. 2. Relative increase of TcPO₂ after simulation compared to normobaric value TcPO₂ < 10 mmHg. (ST 4) corresponds to ischaemia. Final evaluation considers both TcPO₂ absolute value after stimulation and its relative increase compared to normobaric value. Value after stimulation <35 mmHg and concurrently increase <50% compared to the normobaric value (ST5) indicate ischaemia.

Results: We determined 11/31 (35.4%) of discordant pairs between ST1 and ST3 (p <0.001), and 13/31 (31.70%) of discordant pairs between ST3 and ST5 (p<0.001). Combined test ST5 showed highest sensitivity against arterial stenosis: 100% (CI 90.79–100.0). Lowest sensitivity, 58.065 % (CI 50.38–75.45) attributes to ST3.

Conclusion: The highest sensitivity to arterial stenosis attributes to ST5 (TcPO₂ after stimulation <35 mmHg and concurrently relative increase <50% TcPO₂ value before stimulation).

[OP070] DIABETIC FOOT IN CHILDREN AND ADOLESCENTS: THE NEXT EPIDEMIC?

Luca Spazzapan¹, Peschiera del Garda, Italy , Giovanni Papa², Trieste, Italy , Martina Pangos³, Trieste, Italy , Zoran Marij Arnez³, Trieste, Italy , Cristian Nicoletti⁴, Peschiera del Garda, Italy

¹*Casa DI Cura Pederzoli ; Diabetic Foot Unit*

²*Azienda Ospedaliero-Universitaria Ospedali Riuniti; Plastic and Reconstructive Surgery*

³*Azienda Ospedaliero Universitaria Ospedali Riuniti DI Trieste; Plastic and Reconstructive Surgery*

⁴*Casa DI Cura Pederzoli, Diabetic Foot Clinic*

Thursday, May 14, 2015

Free Paper Session: Diabetic Foot 1

Aim: Every year in the USA 13.000 children are diagnosed with type 1 diabetes mellitus (T1DM) and an increased prevalence of type 2 diabetes mellitus (T2DM) in children has been reported worldwide. Foot disorders result in major long-term complications for diabetic patients. Increased risks for lower limb amputation in adults have been associated with peripheral neuropathy with loss of protective sensation, peripheral vascular disease, altered biomechanics. There are few reports concerning foot problems in any paediatric cohort. Aim of this review is to evaluate the current literature about foot problems in children and adolescents with diabetes mellitus.

Method: A systematic review of foot problems in children and adolescents with diabetes mellitus was performed for all articles from January 1994 to August 2014 in MEDLINE, EMBASE, CENTRAL, on hand-searched reference lists from all identified articles. We searched the terms: foot AND pediatric AND children AND diabetes mellitus.

Results / Discussion: International guidelines recommended that children with diabetes have their feet examined since puberty and then at least annually for protective sensation, pulses, skin integrity, and treatable nail problems such as ingrown toenails. Some authors have described that many young patients with DM have foot problems and evidence of early manifestation of peripheral neuropathy in adolescents with T2DM.

Conclusion: With this research we wanted to highlight the importance of foot examination and foot care advice for children and adolescents with diabetes. Larger prospective studies are required to establish prevalence and to optimize preventive interventions.

[OP071] DOCUMENTATION OF DEBRIDEMENTS WITH ACTIVE DEBRIDEMENT SYSTEM AND SUCCESSFUL TREATMENT WITH DIFFERENT COMBINATIONS OF WOUND DRESSINGS IN PATIENTS WITH CHRONIC WOUNDS

Munic Softic¹, Tuzla, Bosnia and Herzegovina , Emir Kabil¹, Tuzla, Bosnia and Herzegovina , Thomas Wild², Wien , Austria , Thomas Eberlein², Wien, Austria , Michael Schmitz³, Oberahr, Germany , Stefanie de Lange⁴, Rengsdorf, Germany , Martin Abel⁵, Neuwied, Germany

¹Special Hospital Bh Heart Center Tuzla

²Woundconsulting GmbH

³Medical Consulting

⁴Lohmann & Rauscher; Medical and Regulatory Affairs

⁵Lohmann & Rauscher GmbH

Thursday, May 14, 2015

Free Paper Session: Diabetic Foot 1

Aim: The Case Series was planned to document the efficacy of an active debridement system in patients with chronic wounds as preparation for treatment with different combinations of wound dressings² with and without anti-microbial capacity.

Method: The debridement was performed using a monofilament fibre debrider¹. Rate of fibrin, granulation and necrotic tissue of the wounds were analyzed by W.H.A.T. system. Wounds were treated using anti-microbial dressings for 14 days for control of infection followed by different combinations of dressings².

Results / Discussion: Chronic wounds of patients with ulcus cruris (10), diabetic foot syndrome (5) or decubitus (4) were debrided with active debridement system. W.H.A.T. analysis revealed total removal of necrotic tissue, reduction of fibrin (79% to 26%) and increase of granulation tissue (21% to 73%). 10 Patients with ulcus cruris (3 months to 17 years) were successfully treated resulting in significant reduction of wound size and improvement of the wound status (example see figure 1) after 3 to 6 weeks. 5 Patients with DFS (6 to 36 months) and 4 cases of decubitus showed significant reduction in wound size (example see figure 2) and status.

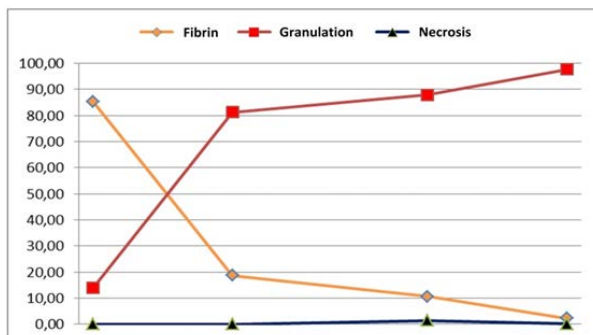


Figure 1: development of wound status of ulcus cruris

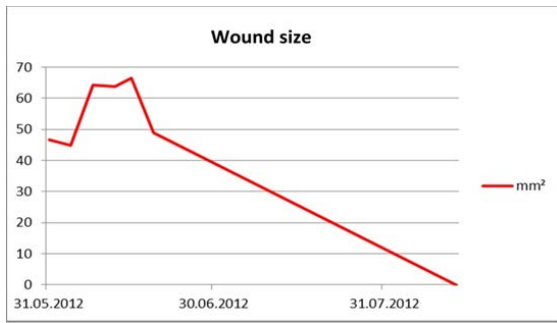


Figure 2: wound size of diabetic foot syndrome

Conclusion: The active debridement system showed a good cleansing effect with total removal of necrotic tissue, reduction of fibrin and increase of granulation tissue. Treatment with anti-microbial dressing controlled infection successfully. Wound therapy with optimized combination of dressings resulted in significant reduction of wound size or even wound closure.

[OP072] EXTENSION AND GRADING OF OSTEOMYELITIS ARE NOT RELATED TO PROGNOSIS AND TO LIMB SALVAGE RATE IN DIABETIC PATIENTS AFFECTED BY CHARCOT OSTEOARTHROPATHY COMPLICATED BY INFECTED ULCERS: A COHORT PROSPECTIVE STUDY.

Luca Dalla Paola¹, COTIGNOLA, Italy , ANNA CARONE¹, COTIGNOLA, Italy , LUCIAN VASILACHE¹, COTIGNOLA, Italy , Maria Catena Principato¹, COTIGNOLA, Italy , MARCO PATTAVINA¹, COTIGNOLA, Italy

¹Maria Cecilia Hospital; Diabetic Foot Department

Thursday, May 14, 2015

Free Paper Session: Diabetic Foot 1

Aim: Diabetic Charcot osteoarthropathy is a progressive disease that causes progressive deformity which easily leads to ulcerations and, consequently, a high risk of amputation. Osteomyelitis with large involvement of midfoot and or ankle is often considered an indication to amputation.

Method: A cohort of diabetic patients affected by Charcot osteoarthropathy complicated by extensive osteomyelitis was studied. Extension of osteomyelitis was studied with plain Rx and MRI. All the patients were treated surgically to obtain eradication of bone infection and stabilization through positioning of external circular frame. Bone biopsies were collected and analyzed. We have analyzed healing rate and limb salvage rate in relationship to extension and grading of osteomyelitis.

Results / Discussion: From January 2010 to May 2014 we have treated 33 consecutive patients affected by Charcot osteoarthropathy complicated by foot and/or ankle ulcers and extensive bone infection. The mean number of osteomyelitic bone segments, diagnosed with MRI, was $3,18 \pm 1,74$. Pathological grading of bone involvement was: grade 1 in 11 patients (33,33%), grade 2 in 7 patients (21,21%) grade 3 in 4 patients (12,12%) grade 4 in 11 patients (33,33%). The mean follow up was $409,35 \pm 154,06$ days. 30 patients healed (90.91%): 28 patients healed (84,85%) and 2 patients healed obtaining fibrous union (6,06%). 3 patients died during follow up. No differences in healing time and number of surgical interventions were founded between patient.

Conclusion: In this cohort of patients we have obtained an high percentage of limb salvage. This result has been obtained despite a diffuse midfoot/hindfoot osteomyelitis. Localization, grading and diffusion of osteomyelitis does not change prognosis and limb salvage rate in the population studied.

[OP073] CUTANEOUS COVERAGE IN DIABETIC FOOT

Oscar Izquierdo¹, Barcelona, Spain , Pere Coca², Sant Boi de Llobregat (Barcelona), Spain , Enric Domínguez³, Barcelona, Spain , Ernesto Muñoz⁴, Barcelona, Spain , Juan Castellanos Robles⁴, Barcelona, Spain , Marta Ferrer⁵, Barcelona, Spain , Antonia Salas⁵, Barcelona, Spain

¹*Parc Sanitari Sant Joan de Déu; Orthopaedic Department. Microsurgery Unit*

²*Parc Sanitari Sant Joan de Déu; Geriatrics*

³*Orthopaedic Department; Microsurgery Unit*

⁴*Parc Sanitari Sant Joan de Déu; Orthopaedic Department*

⁵*Parc Sanitari Sant Joan de Déu; Pressure Ulcers Committee*

Thursday, May 14, 2015

Free Paper Session: Diabetic Foot 1

Aim: To introduce our serie of diabetic patients with ulcers treated with cutaneous coverage.

Method: We have treated 25 cutaneous ulcers.

A debridement was performed in all cases. When the local conditions were optimal we performed the cutaneous coverage, in 10 cases both surgeries were performed at the same time. We used a negative pressure therapy in 48.15% of the cases.

18 grafts and 14 flap were performed. In 2 cases the skin graft was placed on a sheet of artificial dermis placed 4 weeks before.

7 were free flaps and the rest were rotational.

Results / Discussion: 9 were women with 65.29y

The following was 16.65 months

The most affected locations were: leg (7) and forefoot (7)

The most frequent etiology was infection (11)

The average of inpatient was 5.37days/ulcers

Surgical time of surgery was 2h31'

Integration's rate of the grafts was 88.24% and the viability of the flaps was 77%. Of the three flaps that were failed, 2 were resolved with a new flap and the third case with an amputation over the knee

The delay to debridement of the ulcer from its appearance was 7.43 months. The average time to healing of the ulcer was 1.36 months

Conclusion: Reconstructive surgery can maintain a functional foot.

Diabetic foot is a major health problem with a high economic cost. Reconstructions techniques are a valid alternative to conventional care, which reduce healing time and the number of hospital admissions and it can avoid major amputations.

[OP074] EFFECT OF HYALURONIC ACID DRESSING ON DIABETIC ULCER HEALING

Ye-Na Lee¹, Seoul, Korea, Rep. of South , Seung-Kyu Han², Seoul, Korea, Rep. of South

¹*Korea University Guro Hospital; Diabetic Wound Center*

²*Korea University College of Medicine; Department of Plastic Surgery*

Thursday, May 14, 2015

Free Paper Session: Diabetic Foot 1

Aim: To compare the clinical efficacy and safety of hyaluronic acid (HA) dressing with that of conventional dressing material in the management of diabetic foot ulcers.

Method: From May 2013 to February 2014, 19 patients with diabetic foot ulcers were randomized to either the control group with conventional dressing (n=9) or the experimental group with HA dressing* (n=10). Weekly assessments containing wound size and depth, wound characteristics, adverse events, and gross photographs were performed by single investigator. Percentages of reduction in terms of wound area and percentage of increment of healthy granulation tissue were measured for each patient in both groups.

Results / Discussion: By week 3, the mean percentage of wound area reduction was 51.6% in the experimental group and 29.7% in the control group (P=0.184). The mean percentage of wound depth reduction was 59.3% in the experimental group and 50.7% in the experimental group (P=0.712). In addition, the mean percentage of increment of healthy granulation tissue area was 51.7% in the experimental group and 14.6% in the control group (P=0.60). No adverse events related to the study treatment occurred.

Conclusion: HA dressing may have a potential to accelerate the diabetic wound healing.

* Healoderm™

[OP075] SQUARED FASCIOCUTANEOUS RANDOM PLANTAR FLAPS (SFRPF) IN THE TREATMENT OF NONINFECTED DIABETIC PLANTAR ULCERS

Caravaggi Carlo¹, Milan, Italy, Adriana Barbara Sganzaroli², Milan, Italy, Fosca Bona², Milan, Italy, Piero Gherardi², Milan, Italy, Andreo Reho², Milan, Italy

¹*Istituto Clinico Città Studi; Diabetic Foot Clinic*

²*Istituto Clinico Città Studi Via Jomelli 17; Diabetic Foot Clinic*

Thursday, May 14, 2015

Free Paper Session: Diabetic Foot 1

Aim: Foot plantar ulcer in diabetes is a frequent complication with high risk of infection and major amputation. Off-loading cast, suggested as a treatment of choice, has not been widely used due to scarce acceptance by patients and high risk of side effects. We decided to value safe and efficacy of a squared fascio-cutaneous random plantar flap to cover plantar ulcers.

Method: From December 2012 to February 2013 we consecutively enrolled 23 diabetic patients affected by deep neuropathic and neuroischemic plantar ulcer (TUC grade 2-3). A squared fasciocutaneous random plantar flap was performed to cover the ulcers. 9 patients were submitted to a successful percutaneous transluminal angioplasty.

Results / Discussion: Two patients applied weight to the affected side within 1 day postoperatively and were excluded from the analysis. In 16 out of 21 surgical procedures (76%) patients we performed bone surgery as follow: a) 10 metatarsal heads removal; b) 3 uploading distal metatarsal osteotomy; c) 2 first metatarsal-phalangeal joint resection with ray stabilisation by K-wire; e) 1 sesamoidectomy. Healing rate was 100% (23/23). In 18/23 (78%) patients we observed the healing by first intention in a mean time of 30±13 days (median±SD) while in 4 patients by second intention and 1 patient by means of partial surgical revision. Mean healing time by first intention was 30±13 days while healing by second closure was 86±40 days (median±SD) with a total healing time of 44±31 days (median±SD).

Conclusion: Squared fascio-cutaneous plantar flaps can be considered a safe and effective surgical option in treatment of neuropathic plantar ulcer considering high rate of healing, short healing time e low rate of recurrences.